

## DISTAL SHOE APPLIANCE FOR THE LOSS OF DECIDUOUS SECOND MOLAR: A CASE REPORT WITH A TWO YEAR FOLLOW UP

Kanika Singh Dhull, \* Ashish Kalra, \*\* Indira MD, \*\*\* Nikil Jain †

\* Reader, Department of Pedodontics & Preventive Dentistry, Kalinga Institute of Dental Sciences, Bhubaneswar, Orissa, India

\*\* Graded Specialist, Department of Prosthodontics, CORPS Dental Unit, Bhopal, Madhya Pradesh, India

\*\*\* Senior Lecturer, Department of Pedodontics & Preventive Dentistry, JSS Dental College, Mysore, Karnataka, India

† Senior Lecturer, Department of Oral & Maxillofacial Surgery, Kalinga Institute of Dental Sciences, Bhubaneswar, Orissa, India

### ABSTRACT

Preservation of deciduous teeth till its normal exfoliation plays a crucial role in preventive and interceptive dentistry. Premature loss of a deciduous tooth or a group of teeth might lead to wide range of implications. When the deciduous second molar is lost before the eruption of first permanent molar, intra-alveolar type of space maintainer is indicated. This paper describes distal shoe in cases of loss of primary deciduous second molar before the eruption of permanent mandibular first molar.

**KEYWORDS:** Distal shoe appliance; permanent first molar; primary molars; space maintainers

### INTRODUCTION

The preservation of deciduous dentition till its normal time of exfoliation is one of the most important factor involved in preventive and interceptive dentistry.<sup>[1]</sup> The premature loss of deciduous teeth has a wide range of implications which include permanent arch-length decrease, increased overbite, increased crowding, tooth malposition, impactions, arch asymmetries, occlusal impairment and disrupted eruption sequences.<sup>[2]</sup> The causes for loss of deciduous teeth can be deep dental caries, trauma or congenital absence, which may present significant problems for growing child.<sup>[3]</sup> One of the most challenging situation in managing the developing dentition is the premature loss of the second primary molar prior to the eruption of first permanent molar. In the absence of the second primary molar mesial movement and migration of the permanent molar may be expected to occur before and during its eruption and may lead to space loss. It has been reported that about 51% of the prematurely lost first primary and 70% of prematurely lost second primary molars result in a

loss of space and consequent malposition of a permanent tooth in that quadrant.<sup>[4]</sup> Several appliances have been described for space maintenance of severely damaged or lost primary second molars, prior to the eruption of permanent first molars. The most commonly used appliances are Willet's distal shoe, Roche's crown and bar maintainer with distal extension.<sup>[5]</sup> The purpose of this case report is to describe the clinical management of extensively carious primary mandibular molar with a distal shoe appliance.

### CASE REPORT

A female child aged 4.5 years reported to the Department of Pedodontics and Preventive Dentistry with the chief complaint of pain and recurrent swelling in primary mandibular molars on right side. Clinical examination revealed grossly carious primary mandibular right second molar (Fig. 1). Radiographic examination revealed furcal radiolucency and root resorption in relation to primary mandibular right second molar indicating pulp necrosis and bone resorption and radiolucency approximating enamel and dentin in primary mandibular right first molar. The permanent mandibular right first molar showed Stage 6 of development (Nolla's Stages of Tooth Development) (Fig. 2). The primary mandibular right first molar was restored with Glass ionomer restorative material. It was decided to extract primary mandibular right second molar. The primary mandibular right first molar was restored with Glass ionomer restorative material. It was decided to extract primary mandibular right second molar. In this patient Willet's appliance or intraalveolar, eruption guidance appliance type of space maintainer was indicated. The distal extension was calculated radiographically, a cut was made in the cast and wire component was adapted using 19 gauze wire. The procedure was

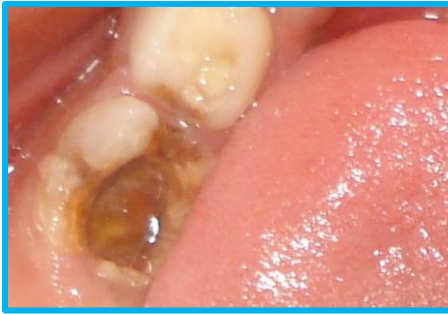

Fig. 1: Grossly carious primary mandibular right second molar

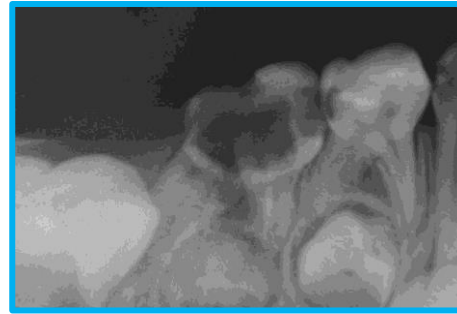


Fig. 2: IOPA radiograph

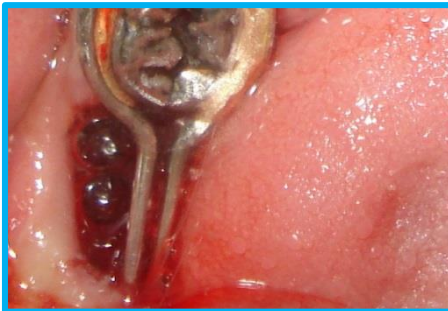


Fig. 3: Appliance cemented in patient's mouth

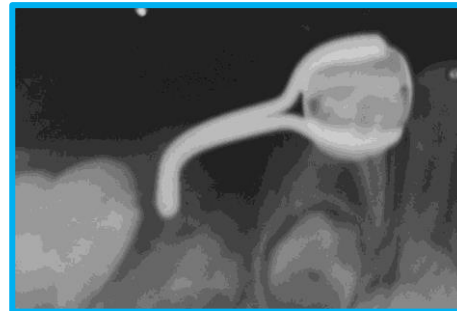

Fig. 4: IOPA radiograph

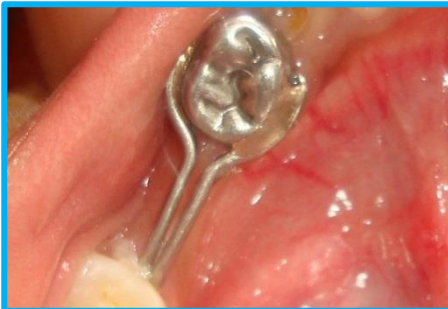

Fig. 5: 2 years showing the erupted permanent right first molar

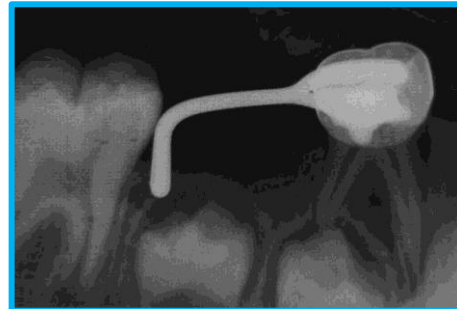

Fig. 6: IOPA radiograph

explained to the patient and informed consent was obtained after extraction under antibiotic coverage, the intra-alveolar projection of the appliance was placed in the socket so as to touch and guide the vertical eruption path of the unerupted permanent first molar on right side of the mandibular arch (Fig. 3). Intraoral periapical radiographs were taken to check the passive contact between the mesial end of the permanent first molar and the appliance before cementation (Fig. 4). The recall visits were planned after every two months to check the condition of the appliance. After 2 years the mandibular permanent first molar erupted (Fig. 5 & Fig. 6).

#### DISCUSSION

Dental caries is the most common reason for the premature loss of deciduous teeth., others being trauma, ectopic eruption, congenital disorders, premature resorption due to arch length deficiency. Depending on the tooth lost, segment

involved, different types of space maintainers must be indicated which help in restoring normal function and eruption of permanent teeth.<sup>[6]</sup>

An ideal space maintainer is one which possesses following qualities:

- Maintain the desired mesiodistal dimension of the space
- Maintain individual functional movement of teeth
- Should be hygienic
- Have good durability
- Have low cost

The diagnosis of a developing malocclusion in the primary dentition does not contraindicate the placement of a distal shoe space maintainer. Even if orthodontic treatment eventually becomes necessary, preventing the mesial drifting of the permanent first molar will facilitate future treatment of the malocclusion by preserving

valuable anchorage.<sup>[7]</sup> The placement of the appliance could prove to be a hazard to children who have congenital heart defects, kidney disease, or a history of rheumatic fever, or to those who have a compromised ability to resist infections, such as uncontrolled juvenile diabetes, certain blood dyscrasias, or generalized debilitation due to poor nutrition or chronic illness. The child's physician should be consulted concerning his medical condition.<sup>[7]</sup> The success criteria of a distal shoe space maintainer, as defined by Baroni et al and Qudeimat et al, is the successful guidance of the unerupted permanent tooth in the arch with no problems associated with the appliance.<sup>[8]</sup> The other factors to be considered, include a long-range plan for space management in a growing child whose occlusion will need surveillance through three developmental stages: the primary, the mixed and the permanent dentition.<sup>[7]</sup>

#### CONCLUSION

In Pediatric Dentistry the main concern of the dentist is to provide maximum benefit to the child with minimum discomfort, more co-operation and less chair side time. In this case distal shoe appliance was given which was well accepted by the child. The appliance guided the eruption of permanent molar in place.

#### CONFLICT OF INTEREST & SOURCE OF FUNDING

The author declares that there is no source of funding and there is no conflict of interest among all authors.

#### BIBLIOGRAPHY

1. Norman PM, Henery GE. Functional maintenance of arch length. *ASDC J Dent Child*. 1984;51:190-3.
2. Owen DG. The incidence and nature of space closure following the premature extraction of a deciduous teeth: a literature survey. *Am J Orthod*. 1971;59:37-49.
3. Graber TM. Preventive orthodontics. In: Graber TM, editor. *Orthodontics principles and practice*, 3rd ed. Philadelphia: WB Saunders Company; 2001. p. 627-67.
4. Jeffrey A. Management of the developing occlusion. In: McDonald RE, Avery DR, editors. *Dentistry for the child and adolescent*. 8th ed. Philadelphia: Harcourt India Private Limited. 2001. p. 625-683.
5. Garcia-Godoy F. A distal screen for space maintenance of unerupted permanent first Molars. *Acta Odontol Pediat*. 1983;4(2):55-58.
6. Nayak UA, Loius J, Sajeev R, Peter J. Band and loop space maintainer - made easy. *J Indian Soc Pedod Prev Dent*. 2004;22:134-6.
7. Hicks EP. Treatment Planning for the Distal Shoe Space Maintainer. *Dent Clin North Am*. 1973;17(1):135-150.
8. Brill WA. The distal shoe space maintainer chair side fabrication and clinical performance. *Pediatr Dent*. 2002;24:561-5.